

CLINICAL GUIDELINES FOR THE MANAGEMENT OF PERIORBITAL CELLULITIS IN CHILDREN

1. INTRODUCTION

Periorbital Cellulitis is an uncommon but important infection in childhood. Complications include orbital and intracranial extension of infection. This guideline is proposed to promote consistency in the management of such children.

2. PURPOSE

To have evidence based treatment of all patients admitted with Periorbital Cellulitis and institute proper referrals and management for prevention of serious complications associated with this condition. This will be followed in all patients admitted to children's ward with Periorbital Cellulitis.

3. SCOPE

To be used by Paediatricians, Ophthalmologists and ENT surgeons in management of children with Periorbital Cellulitis.

4. RATIONALE

This guideline is proposed so that we have consistency of management of children with Periorbital Cellulitis in form of referrals, antibiotics and follow-up of the patient and early intervention in form of imaging to be made to prevent the cranial and other serious infections in these patients.

This guideline replaces the previous guideline following audit and consultation with Paediatrics, Ophthalmology, ENT, Microbiology and Radiology. This takes into account changes in service provision.

MANAGEMENT OF CHILDREN WITH PERIORBITAL CELLULITIS (SEE FLOW CHART): ALL THE PATIENTS REFERRED BY GP OR A&E SHOULD BE ADMITTED UNDER PAEDIATRICS.

PERIORBITAL OEDEMA / ERYTHEMA ONLY:

These are the category of patients with only oedema or erythema without other ocular or systemic involvement (see criteria below). These patients have clear white eyes (conjunctivae) with full range of normal eye movements. Such patients can be treated with oral antibiotics and reviewed at 24 hours to determine improvement. If improving they can be discharged home with oral Co-Amoxiclav for 7-14 days and reviewed at the end of the antibiotic course.

PERIORBITAL OEDEMA / ERYTHEMA WITH ONE OR MORE OF THE FOLLOWING:

- Child < 3 yrs of age
- Pyrexia >38
- Pain on eye movement
- Decreased eye movement
- Altered vision, or Relative Afferent Pupillary Defect (RAPD)
- Proptosis or chemosis

- Optic disc swelling
- Patients in whom it is not possible to examine eyes
- Patients who are toxic with systemically unwell.

These are the patients who can have potential complications and thus they need admission, blood tests, IV antibiotics, ophthalmology within 8 hours, and ENT opinion within 24 hours (see flow chart). Also at admission consider the need for a CT scan urgently (see indications) to look for extension in orbits or CNS in such patients.

There is limited Ophthalmology and ENT cover at weekends at JPUH. Therefore patients requiring admission at the weekend should be transferred to NNUH in liaison with the on-call Ophthalmology & ENT teams at Norwich.

FURTHER MANAGEMENT OF ADMITTED PATIENTS:

- IF CHILD IS IMPROVING AND BLOOD CULTURE ARE NEGATIVE at 48 hours then these patients can be managed with oral antibiotics for total 10 days and joint decision to be made for discharge.
- IF THERE IS LITTLE CLINICAL IMPROVEMENT AND OR BLOOD CULTURE IS POSITIVE at 48 hours then child should have up to 5 days of IV antibiotics followed by 5 days of oral antibiotics and joint decision to be made for discharge. Switching to oral antibiotic therapy should be considered after the patient is afebrile for at least 24 hours, and the eyelid and orbital findings have begun to improve substantially.
- **ALL** patients should have out-patient appointment in *paediatric ophthalmology clinic* with orthoptics **at 1 week**, and may have out patient appointment at the end of the course with paediatric consultant.

INDICATIONS FOR CT SCAN:

CT requests should state "CT Sinuses (Medtronic protocol)"

- No improvement or deterioration at 36 hours.
- Swinging pyrexia not resolving within 36 hours.
- Proptosis and/or chemosis.
- Completely closed eye – unable to assess
- Ophthalmoplegia.
- Deteriorating vision (acuity or colour).
- Development of RAPD
- Bilateral ocular signs
- If there are central symptoms or signs (e.g. drowsy, fit, cranial nerve lesion, vomiting, headache).

5. EVIDENCE

1. Powell K.R. Orbital and periorbital cellulites, Paediatrics in Review Vol.16 No 5 May 1995.
2. Uzcategui N, Warman R, Smith A. Clinical Practice Guidelines for the management of Orbital Cellulitis. J Pediatr Ophthalmology and strabismus. 1998;35: 73-79.

3. Molarte SB, Isenberg SJ. Periorbital Cellulitis in Infancy. J Paed Ophth Strab 1989; Oct: 232-4
4. Lessner A, Stern GA. Preseptal and Orbital Cellulitis. Inf dis clin of North America Vol 6, 4, Dec 1992, 933-952.
5. Dudin, A, Othman. A (1996). Acute periorbital Swelling: Evaluation of Management Protocol. Pediatric Emergency Care (12) 1: 16-20.
6. An evidence based review of Periorbital Cellulitis. Clinical Otolaryngology 2011; 36 (1):75-64.

6. ENDORSMENT

Dr J Chapman -Consultant Paediatrician
Dr R Stocks -Consultant Paediatrician
Dr V Jayalal – Consultant Paediatrician
Dr S Nirmal – Consultant Paediatrician
Mr C Philpott -Consultant ENT
Mr P Prinsley -Consultant ENT
Mr P Tassone -Consultant ENT
Mr TKH Butler -Consultant Ophthalmologist
Mr B JL Burton -Consultant Ophthalmologist
Mr C Goldsmith - Consultant Ophthalmologist
Mrs B Hemmant - Consultant Ophthalmologist
Mr S Mukherji – Consultant Ophthalmologist
Mr A Prabhu – Consultant Ophthalmologist
Mr NJ Watson -Consultant Ophthalmologist
Dr K Ashraf –Consultant Radiologist

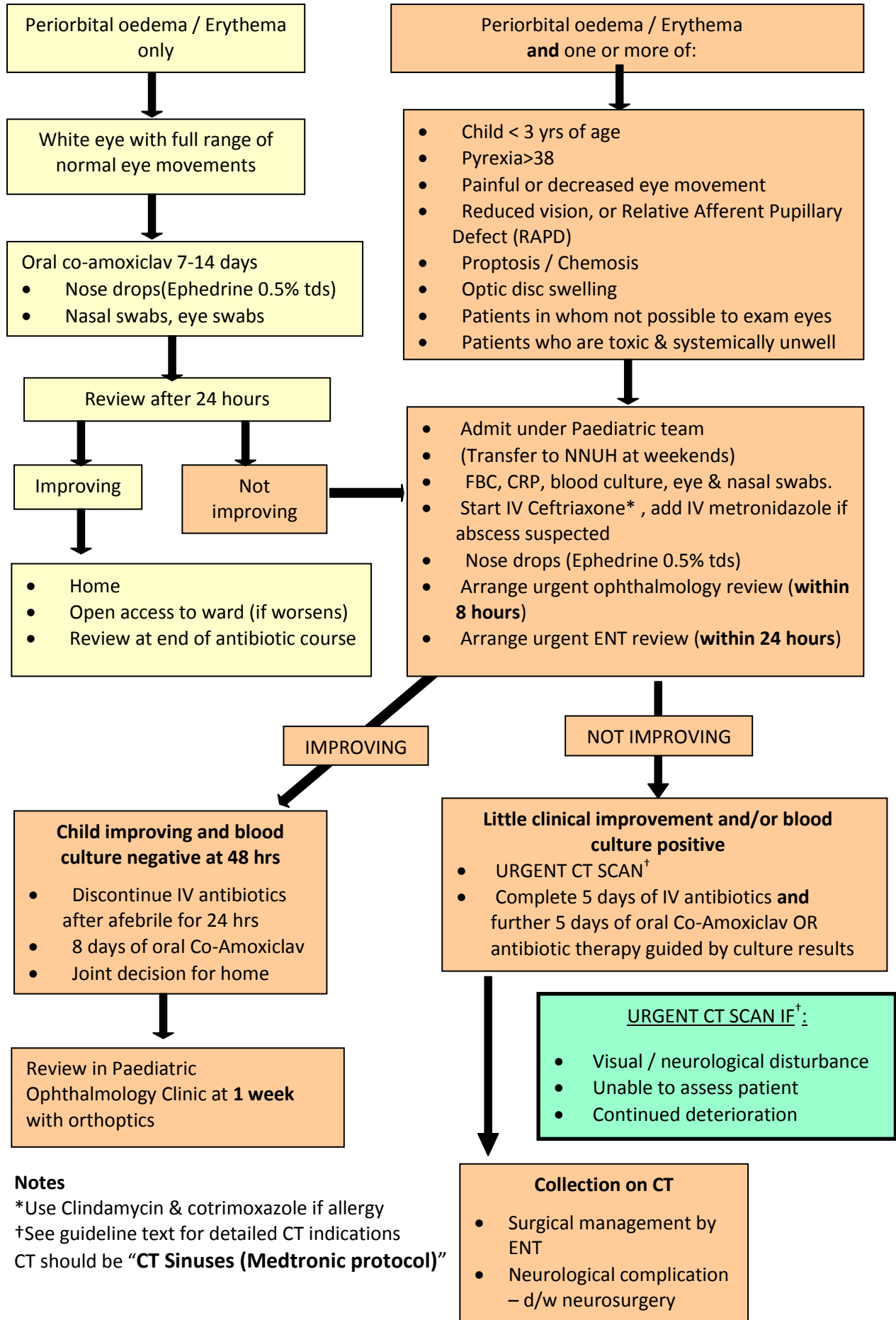
7. AUDIT INDICATORS

- Patient admitted according to guidelines and treated.
- Proper referrals made in required patients.
- Antibiotics given as per guidelines.
- Follow up appointments given to those who needed.

8. AUTHOR AND DATES

Authors: Dr J Chapman & Dr R Parikh
Issue date: March 2004
Review date: March 2005
Reviewed by: Dr J Chapman, Consultant Paediatrician
Issue date Version 2: May 2005
Review date: May 2007
Reviewed by: Mr TKH Butler, Consultant Ophthalmologist
Issue Date Version 3: February 2009
Reviewed by: Mr TKH Butler, Consultant Ophthalmologist & Dr L Ratnayake, Consultant Microbiologist
Issue Date Version 4: April 2014
Review date: April 2017
KEYWORDS: eye, inflammation, infection

CLINICAL GUIDELINE FOR MANAGEMENT OF PERIORBITAL CELLULITIS



Notes

*Use Clindamycin & cotrimoxazole if allergy
 †See guideline text for detailed CT indications
 CT should be “**CT Sinuses (Medtronic protocol)**”